



DATE PRESENTING CLINICAL SIGNS

3.3.26

PATIENT

Wheezy Pargan

SPECIES

Feline

BREED

DSH

SEX

FS

AGE

10.9.13

WEIGHT

14.3lbs

INTERPRETED BY

Maggie Machen Lamy,
DVM, DACVIM
(Cardiology)

HOSPITAL NAME

Homeward Bound VS

REFERRING VET

Dr. Dorn

INVOICE

47077

History: Diagnosed with a heart murmur at wellness visit on 8/25/2025, was recommended at that visit to get an echocardiogram, BNP on bloodwork was normal.

-Current medications: Amlodipine 2.5mg - 1/4 tablet once daily, Phenobarbital 15mg - 1/2 tablet q12h.

-Sedation used: Not required to complete full diagnostic ultrasound.

-Pertinent previous ultrasound results: No previous.

-STAT: Not requested.

-Imaging performed by: Stephanie Warga RDCS, RVT.

ECHOCARDIOGRAM FINDINGS

2D, m-mode, color flow and doppler imaging is available. The left ventricular wall is irregular with mild focal septal thickening and a borderline normal free wall. There is a mildly hyperechoic endocardium consistent with fibrosis. The papillary muscles are mildly hyperechoic. The left atrium is normal in size.

The right atrium is normal in size. The right ventricle appears normal. The mitral valve is normal in appearance with mild MR. No TR. Blood flow through the RVOT is normal. The blood flow through the LVOT is mildly elevated with a dynamic profile. Trivial AI. Aortic root is normal. No pleural or pericardial effusion seen. No obvious cardiac tumors.

CARDIAC CHART

FELINE CARDIAC PARAMETERS	BODY WEIGHT (kg)	HR (BPM)	IVSd (cm) (Moise, Pipers)	LVIDd (cm) (Moise, Pipers)	LVWd (cm) (Moise, Pipers)	FS (%)	EF (%)
NORMAL PARAMETER	-----	150-240	3.5-0.55	<2 (mean 1.5)	3.5-0.55	35-67	80-100
PATIENT	6.5	NM	0.62	1.36	0.55	55	88
FELINE CARDIAC PARAMETERS	LA/AO (Boon)	LA/AO HEART BASE (Swe) (Abbott)	LA 2D short axis Base view (cm) (Abbott)		LVOT VEL (m/s)	RVOT VEL (m/s)	E max (m/s)
NORMAL	<1.5	<1.3	<1.2		<1.6	<1.3	<0.9
PATIENT	NM	1.2	1.2		3.4	1.2	NM

Adapted from June Boon, Veterinary Echocardiography, 1998
Abbott J & MacLean H JVIM 2006;20: 111-119, Moise et al. Am J Vet Res 47:1476, 1986. Pipers et al. Am J Vet Res 40:882, 1979.

INTERPRETATION OF THE FINDINGS & FURTHER RECOMMENDATIONS

The cause of the murmur is an LVOT obstruction secondary to abnormal valve motion, resulting in mild MR. The LV is abnormal, with mild focal septal hypertrophy, which should be monitored going forward as these findings may suggest early HOCM. The LA is normal, and no additional issues are identified.

Given these findings, no medications are indicated. Should the degree of hypertrophy worsen, or a more significant obstruction be identified, Atenolol may be recommended in the future pending further heart rate assessment.

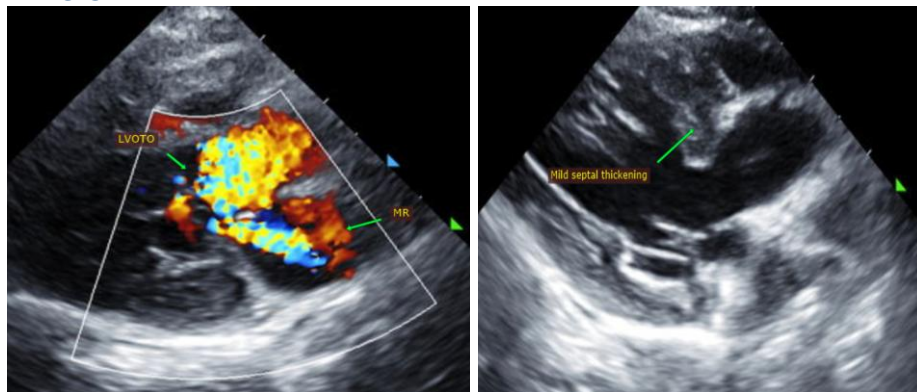
Prognosis is guarded prior to assessing for progression.

Anesthetic risk is considered mild. Additionally, drugs that stimulate heart rate should be avoided unless clinically necessary (glycopyrrolate, atropine). A reasonable protocol includes opioid/benzodiazepine premedication, propofol induction, isoflurane maintenance. Additionally, steroids should be used with caution on older cats, as even a 'normal' geriatric heart can develop evidence of intolerance and fluid retention.

Monitor for any development of clinical signs, including labored breathing or signs of a blood clot (paralysis, neurologic change).

A recheck echocardiogram is recommended in 6-12 months to screen for any evidence of progression.

IMAGES



The information and recommendations provided are based on the images presented by the referring veterinarian. No evaluation can be communicated regarding pathology that was not visible in the image/video clips provided.

Thank you for this referral. This report was generated using transcription software, and minor dictation errors may be present. If the clinical or image interpretation does not parallel your findings or if I can be of any further assistance, please contact me.

Maggie Machen Lamy, DVM
Diplomate of the American College of Veterinary Internal Medicine (Cardiology)
info@sonopath.com